

A Ring is Not Just a Ring: Creative Uses of Ostomy Accessories

Juliet Smith, RN, BSN, CWOCN and Chenel Trevellini, RN, BSN, CWOCN

New York-Presbyterian, The University Hospitals of Columbia and Cornell, New York, NY

Linda Lankenau, RN, MSN, CWON, Pennsylvania Hospital, Philadelphia, PA

Susan Maditz, RN, MSN, CWOCN, Brenda Uphold, RN, BSN, CWON and Janice K. Shreve, RN, MSN, CNS, APRN-BC, CORLN

West Virginia University Hospital, Morgantown, WV

Susan Reif, RN, BSN, CWOCN and Antje Bogart, RN, MSN, CWON, Cleveland Clinic Home Care, Cleveland, Ohio

Overview

The WOC Nurse should use relevant clinical approaches, research, and products to solve complex problems. Skin barriers are an important tool in managing not only ostomies but other challenging clinical problems.

Key clinical objectives involve protection of skin, containment of drainage, enhancement of patient comfort, optimization of nursing time, and cost containment. Through the use of **Adapt** Barrier Rings, we have been able to address many of these objectives. We have found that although the product is provided as a ring, we often use it in different shapes and applications to accomplish our clinical goals.

Barrier rings are more durable than paste or paste strips and they do not contain alcohol, which makes them ideal when working with patients who have liquid drainage and eroded skin. The following case studies illustrate some patients with unique challenges and their outcomes.

Case Study 1: Loop Ileostomy with Rod

History: A 56-year-old, obese white male was admitted with rectal cancer. He underwent a low abdominal resection that resulted in a temporary loop ileostomy. He also had a history of diabetes and hypertension. The patient was not preoperatively sited or marked.

Problem: The stoma was located in a deep abdominal skin fold, which was even more evident when the patient was sitting. This location created a high risk for leaks and consequent skin erosion, pain, the need for frequent pouch changes, and increased cost associated with care. Use of a temporary “rod” under the loop stoma further threatened adequate seal and wear time (Photo 1).

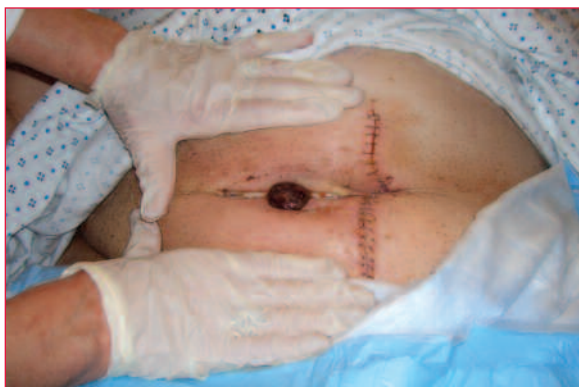On assessment, it was determined that the best solution would be a flexible, drainable, extended wear barrier pouching system with a product to build up medial and lateral side abdominal creases once the bridge was removed, as well as during the time the bridge was in place. Additionally, the patient and his wife elected not to have a

visiting nurse secondary to personal cost. Several phone calls to the hospital WOC Nurse and one visit with an MD and WOC Nurse helped bridge the recovery period.

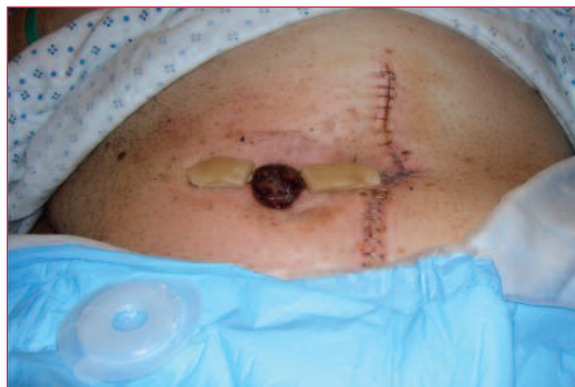Positive Outcomes: A flexible pouch (Hollister stock number 8531) and a flat Adapt Barrier Ring (Hollister stock number 7805) and **Adapt Paste** were used. The Adapt Barrier Ring was separated in half and placed over the “bridge” (Photo 2). Adapt Paste was applied to the back of a custom-cut pouch and placed over the stoma, with the patient lifting his upper abdominal skin during the pouch application to help decrease the depth of the significant skin creases (Photos 3 and 4).

Wear time was consistently four days without leaks. This patient did not learn to change his own pouch; he relied on his willing and adept wife. The family also had the support of the Hollister **Secure Start** Program, which was a very helpful and satisfying partnership.

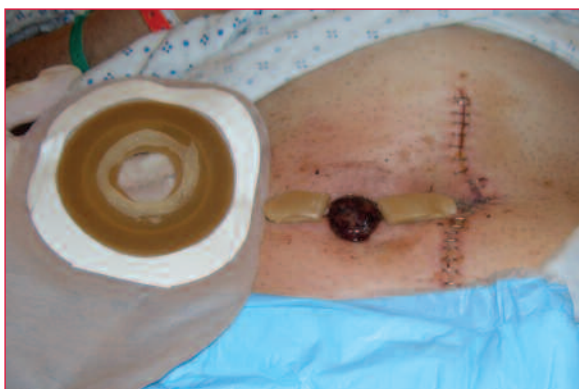One week post-discharge, his midline incision opened vertically approximately three inches and to depth of one inch very near the stoma. His wife learned to pack the wound with a calcium alginate, and pouch wear time was preserved with no leaks. Although the stoma was initially very dark, it “pinked up” within two weeks and remained viable until the ostomy reversal procedure.



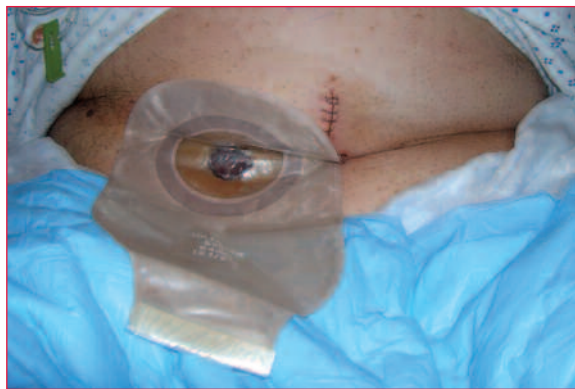Case 1 Photo 1



Case 1 Photo 2



Case 1 Photo 3



Case 1 Photo 4

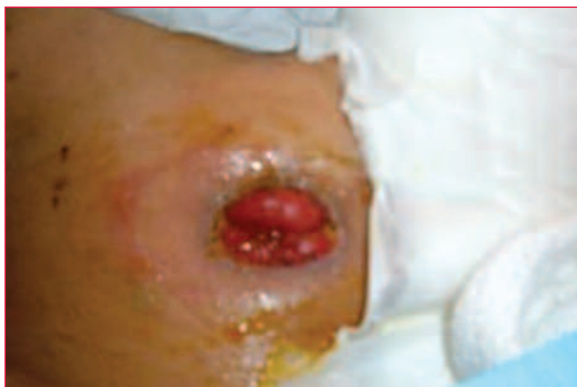Case Study 2: Oval Stoma

History: The patient is a 52-year-old female with a psychiatric history of generalized anxiety disorder, depression, and bipolar disorder. She has a history of IBD and has an ileostomy (Photo 1).

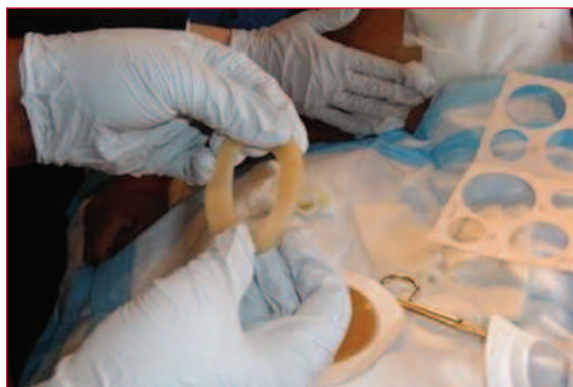Problem: The patient is frequently admitted for contact dermatitis and cellulitis of the peristomal skin. During one such admission, the

patient was found to have peristomal erythema. The patient's stoma is oval and flush with the surrounding skin.

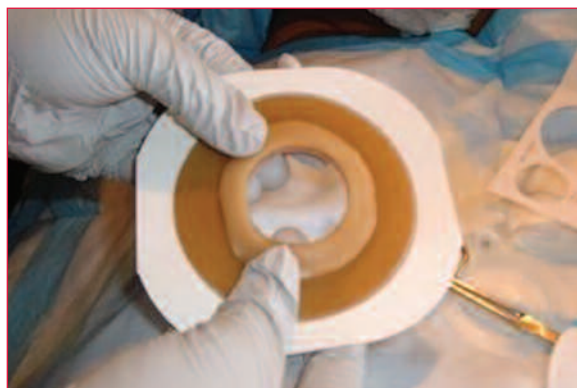
Positive Outcomes: The use of a **New Image** Convex Skin Barrier, along with an Adapt Barrier Ring stretched to an oval shape, helped to ensure a good seal (Photos 2 and 3). The successful pouching prevented leakage and peristomal skin damage (Photos 4 and 5).



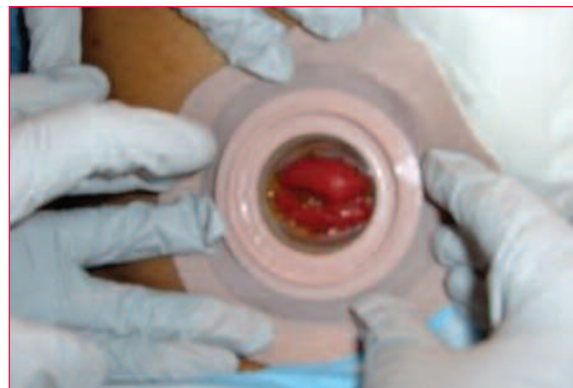
Case 2 Photo 1



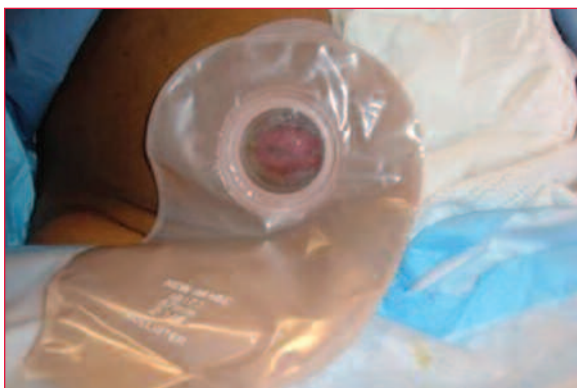Case 2 Photo 2



Case 2 Photo 3



Case 2 Photo 4



Case 2 Photo 5

Case Study 3: Abdominal Wound

History: A 37-year-old white female presented with complaints of malaise and intermittent abdominal pain for the past three weeks. The patient had been seen multiple times at outside hospital emergency rooms and was diagnosed with portal vein thrombosis. The patient had been having worsening abdominal distention. Her past medical history was negative for blood clots and positive for anxiety, esophageal reflux, gastroesophageal reflux, and hyperlipidemia.

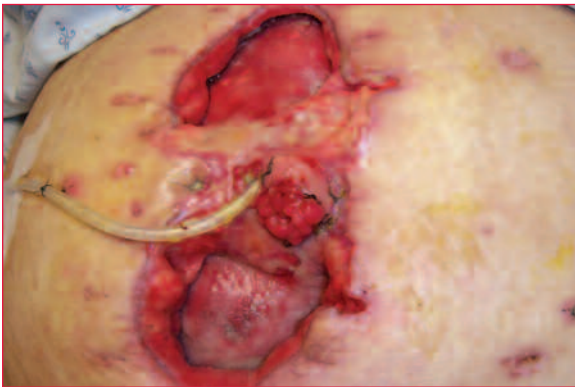The patient underwent a CAT scan with IV contrast. The scan impression was suggestive of malrotation or an internal hernia and free intra-abdominal fluid consistent with ascites. There also was small-bowel wall edema distal to the point of concern for a malrotation internal hernia. Small bilateral pleural effusions were noted. Additionally, there was a filling defect within the superior mesenteric vein consistent with thrombus extending to the portal

vein. Edematous changes were noted within the small bowel that may have been related to venous congestion and ischemia due to this thrombosis. No pneumatosis or portal venous gas was seen.

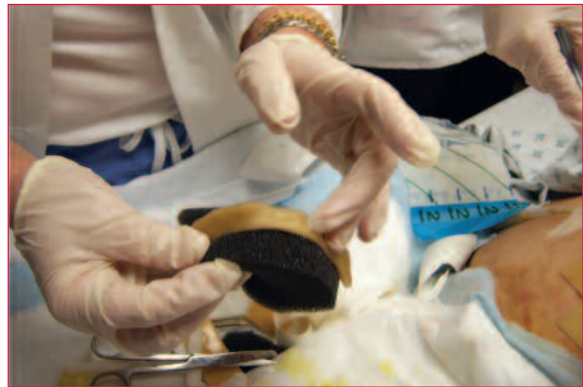The patient underwent exploratory surgery and had a small bowel resection, exploratory laparotomy, and abdominal washout of her open abdomen.

Problem: There were two open abdominal wounds with a centrally located un-matured stoma (Photo 1). The abdominal wounds required negative wound pressure therapy placement for upper and lower abdominal wound management and isolation of a high output stoma.

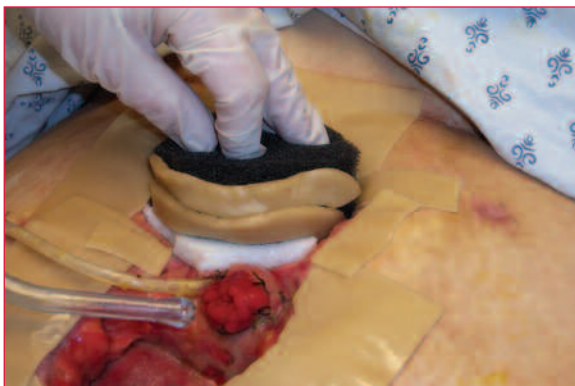
Positive Outcomes: To manage the wound and stomas, Adapt Barrier Rings, Adapt Paste, a high output pouch, and negative wound pressure therapy were utilized to maintain a secure seal (Photos 2 through 4).



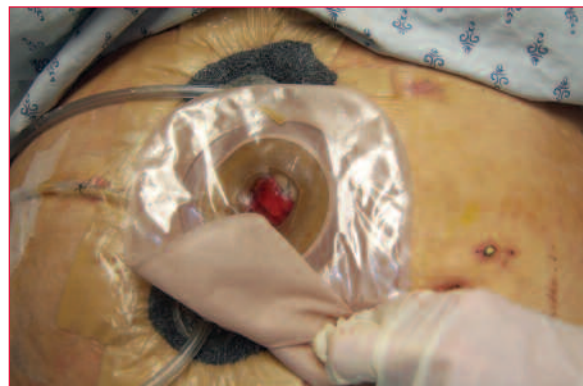
Case 3 Photo 1



Case 3 Photo 2



Case 3 Photo 3



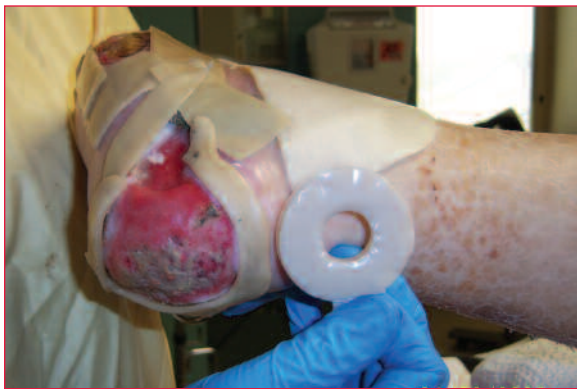
Case 3 Photo 4

Case Study 4: Diabetic Foot Ulcers

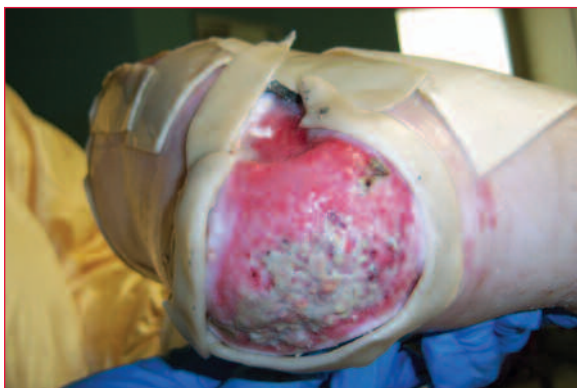History: A 56-year-old man was admitted to WVUH with long-standing diabetic foot ulcers, PAD, CAD, history of bypass, poorly controlled diabetes, COPD, hypertension, obesity, end-stage renal disease, and was on hemodialysis. He had a previous amputation of digits two through five, followed by a first digit/great toe amputation.

Problem: The amputation left him with an open transmetatarsal wound as well as a heel ulcer. The wound was infected with VRE and E. coli. It was felt that negative pressure wound therapy would give the best chance of healing. Securing the dressing to the foot proved to be a difficult task.

Positive Outcomes: Adapt Barrier Rings were utilized to circle the transmetatarsal and heel wounds (Photos 1 and 2), providing a landing area for the drape. The ring protected the periwound skin, absorbed excess drainage from around the wounds, and ensured a successful seal for a full 48 hours.



Case 4 Photo 1



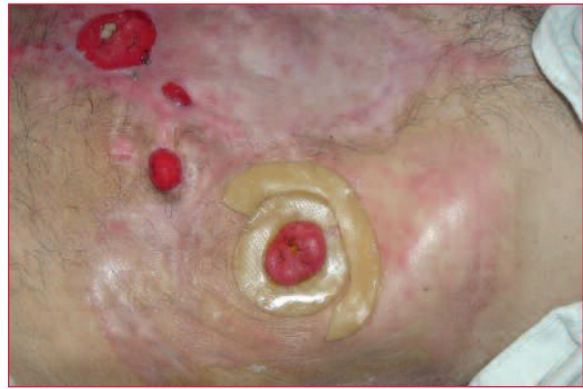Case 4 Photo 2

Case Study 5: Abdominal Fistulas and a High Output Ileostomy

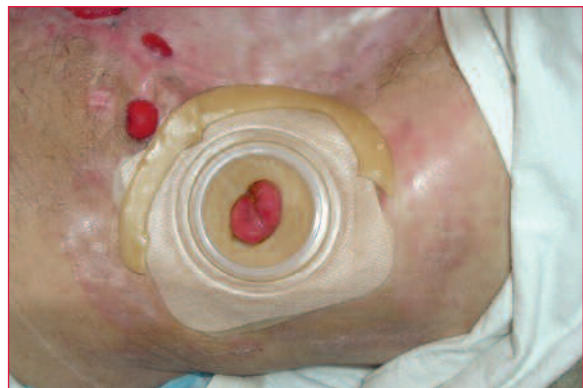History: The home care WOC Nurse admitted a patient to home care with four abdominal fistulas and a high output ileostomy, which was located right under his left lower rib in a deep "well."

Problem: The ostomy was very proximal in the ileum and the stomal tissue moved up above the skin level and then spontaneously retracted, spouting watery effluent under high pressure due to its proximal location in the gut.

Positive Outcomes: After trying three or four different pouching systems, the WOC Nurse discovered that building up the peristomal skin with two to four Adapt Barrier Rings layered consecutively around each other expanded the adhesiveness of the foundation (Photo 1). This helped to increase the wear time to three to four days. The patient was able to snap on a high output pouch. He also used pieces of the Adapt Barrier Ring as a dam between the abdominal fistula and the tape on the skin barrier of the pouching system to enhance the seal (Photo 2).



Case 5 Photo 1



Case 5 Photo 2

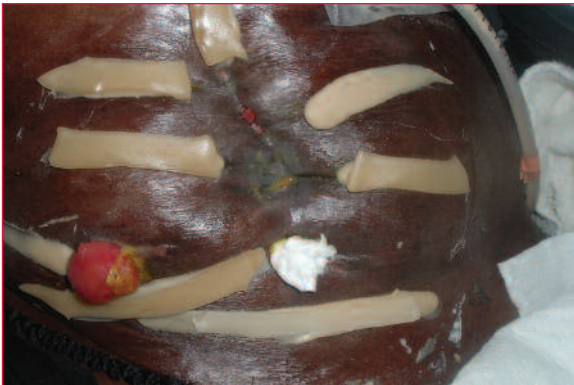Case Study 6: Abdominal Fistulas

History: An African-American female patient admitted to home care had three abdominal fistula openings in the midline of her abdomen after extensive cancer surgery.

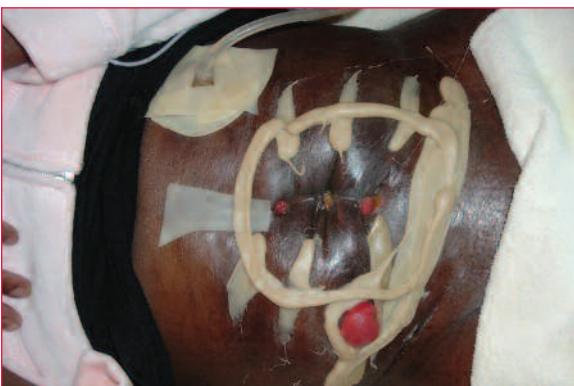Problem: The deep creases in her abdomen caused extensive and immediate pouch leakage after each application.

Positive Outcomes: This was resolved by using six to 10 Adapt Barrier Rings, which were molded to fill in the abdominal creases (Photos 1 and 2). The Adapt Barrier Rings restored her ability to live a more normal life with an intact high-output fistula pouch.

This patient was delighted and so grateful that her new "foundation" for the pouch application was so dependable. She further said that it has given her "life back," knowing that her abdomen will stay dry and the seal of her pouch will stay intact for four days or longer due to the creative use of those "sticky" Adapt Barrier Rings.



Case 6 Photo 1



Case 6 Photo 2

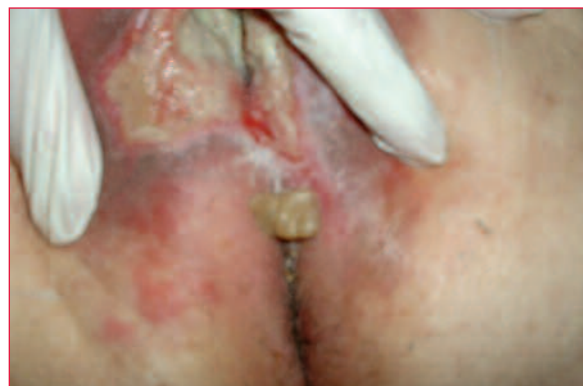Case Study 7: Perineal Wound

History: A 29-year-old male presented with recurrent perirectal abscess. He had a history of Crohn's disease, recurrent pilonidal cyst x2 with previous excision, acute pancreatitis, and status post laparoscopic ileocolic resection. Initially, he presented to the outpatient clinic with complaints of pain and swelling in the area of the previous pilonidal disease. The area was aspirated and found to have no pus, treated with oral antibiotics, and sitz baths.

Subsequently, he presented to the emergency department again with the same complaint. The area was again aspirated, antibiotics were prescribed, and there were no signs of acute problems. The following day, the patient called his physician with complaints of fever, increasing pain, and increased swelling. He was admitted to the hospital and was found to have an 8x4 cm area of induration and cellulitic skin in the area of left superior gluteal cleft with a small amount of pus. He then had an excision of a left gluteal pilonidal abscess cavity with rigid protoscopy for infected pilonidal sinus.

Problem: The wound site was initially treated with Betadine-soaked gauze then, prior to hospital discharge, the treatment was changed to negative pressure wound therapy (NPWT). Due to the wound location and associated challenges of the anatomy, achieving a secure seal was difficult.

Positive Outcomes: An Adapt Barrier Ring was utilized in conjunction with the NPWT dressing and an immediate secure seal was achieved (Photo 1). The wound site demonstrated progress. However, after several dressing changes, the patient was unable to tolerate the NPWT and treatment was changed. The use of the Adapt Barrier Ring allowed the NPWT dressing to be changed every 72 hours and maintained a satisfactory seal without the need for more nursing visits for dressing leaks.



Case 7 Photo 1

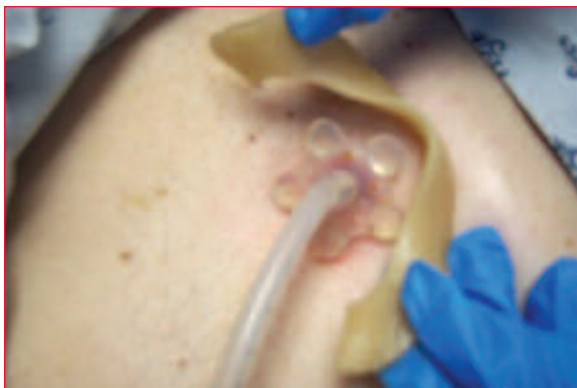Case Study 8: Gastrostomy Tube

History: A 48-year-old male presented following a motor vehicle accident. The patient was unresponsive at the scene and upon arrival to the emergency department at WVUH. A CT C-spine was positive for jump facet, C6 on C7, with severe spinal canal compromise. The initial clinical impression revealed a fracture-dislocation of the cervical spine with spinal cord injury, blunt head trauma, and acute alcohol intoxication.

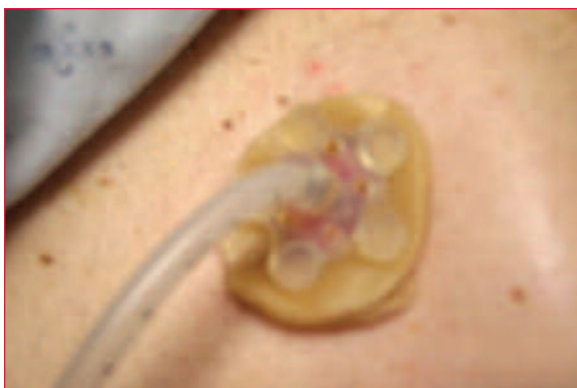Over the course of time, the working diagnosis progressed to hospital-acquired pneumonia, Stage IV sacral ulcer, bipolar disorder, paralysis secondary to the motor vehicle accident, depression, gout, gastroesophageal reflux disease, malnutrition, history of diabetes, history of urosepsis, diverting colostomy, and G-tube dependent.

Problem: Skin issues related to the gastrostomy tube.

Positive Outcomes: An Adapt Barrier Ring was flattened and utilized around the base of the G-tube. This helped to prevent skin erosion from the projections underneath the bumper plate. The addition of the Adapt Barrier Ring also stabilized the tube and prevented leakage. (Photos 1 and 2)



Case 8 Photo 1



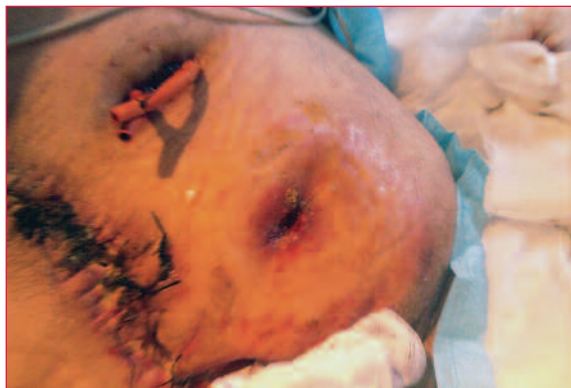Case 8 Photo 2

Case Study 9: Multiple Stomas

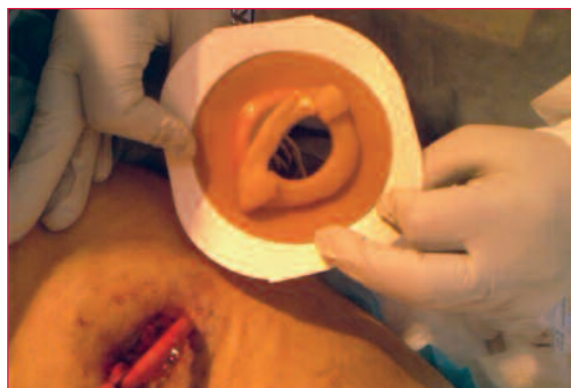History: A 50-year-old male presented with a history of DMII, HTN, CAD, and recurrent diverticulitis. The patient had an emergent sigmoid colectomy and ileostomy for a partial large-bowel obstruction. Subsequently, the patient developed an anastomotic leak from the colorectal anastomosis and had to have a loop transverse colostomy to divert the stool. He also had an open midline wound with a fistula and he required a second ileostomy, which was located in the LLQ below the transverse loop colostomy (Photo 1).

Problem: The ileostomy stoma became retracted and posed a challenge for pouching. The transverse colostomy had a rubber catheter supporting the loop of bowel that created additional challenges.

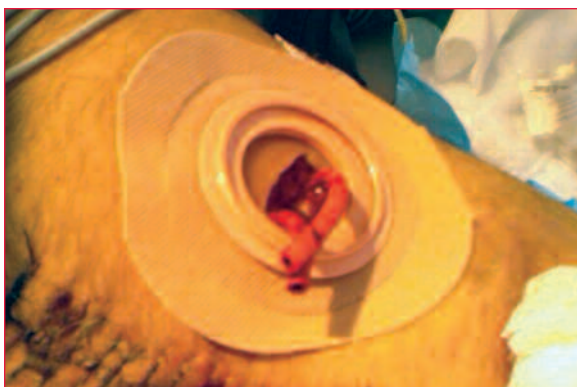Positive Outcomes: Creative use of the Adapt Barrier Ring and a New Image Convex Skin Barrier for the loop colostomy helped to protect the skin and maintain a secure seal (Photos 2 and 3). With the aid of convexity and the Adapt Barrier Rings, success in preventing leakage from the high output ileostomy was achieved (Photos 4 and 5).



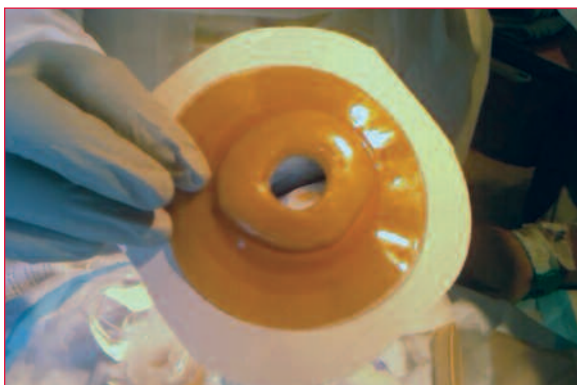
Case 9 Photo 1



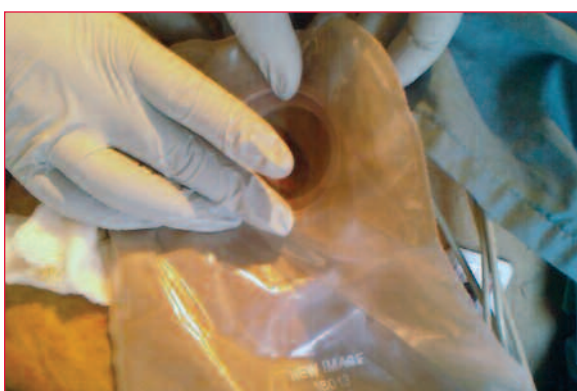
Case 9 Photo 2



Case 9 Photo 3



Case 9 Photo 4



Case 9 Photo 5

Financial Assistance/Disclosure

The support of Hollister Incorporated for this clinical presentation is gratefully acknowledged.

Hollister and logo, Adapt, and New Image are trademarks of Hollister Incorporated. Secure Start is a service mark of Hollister Incorporated.
© 2009 Hollister Incorporated.

910704-609

Conclusion

When compared to previous management methods, the innovative use of Adapt Barrier Rings has allowed for versatility and improved outcomes for many patients who present unique challenges. Some of the key clinical advantages include:

- Adapt Barrier Rings are easy to use and, therefore, the procedures can be simplified for family and staff. This can help to provide continuity of care when the WOC Nurse is not available.
- They are easily molded and shaped for difficult locations. This means one product is compatible with many modalities of care and can address a variety of clinical applications. This helps to minimize products stocked in the facility.
- The Adapt Barrier Rings are alcohol-free. This eliminates stinging when applied to skin surfaces that are already compromised.
- Because the Adapt Barrier Rings are extended wear, they resist erosion from fluid which can enhance wear time and decrease nursing time spent with complex pouching procedures, especially when compared to ostomy pastes.

As Presented at

WOCN Society 41st Annual Conference

June 6-10, 2009

St. Louis, MO



Hollister Incorporated

2000 Hollister Drive
Libertyville, Illinois 60048 USA
1.888.740.8999

Distributed in Canada by

Hollister Limited

95 Mary Street
Aurora, Ontario L4G 1G3
1.800.263.7400

www.hollister.com