

Use of a CeraPlus Skin Barrier

with Remois Technology*

Case Study 2

Abstract

There is a high incidence of peristomal skin complications, with more than half of all people living with an ostomy experiencing a peristomal skin issue at some point in their lifetime¹. The types of complications, the reasons for them, and the solutions used to treat them can vary widely. For clinicians, managing these peristomal skin complications takes time and effort. For patients, sore peristomal skin can have a huge impact on their quality of life. Peristomal skin complications are the most common post-operative complication following creation of a stoma². One such story will be shared in this case study.

Aim

To visibly improve and maintain peristomal skin integrity by finding a suitable skin barrier formulation for the patient, and ensuring a proper skin barrier fit around the stoma.

Setting

The patient is a 49 year female who underwent a sub-total colectomy and proctectomy with end ileostomy formation.

Patient Overview

After initial difficulties with pouches leaking she settled with a one-piece soft convex pouching system with which she remained leak free. She would change on alternate days and felt confident and able to restart her social activities following a difficult and emotional period.

Problem

At the first annual review she mentioned that her peristomal skin had turned sore and itchy in places (**Photo 1**). On checking her pouch changing technique, all was correct. She was seen in clinic and had a skin swab taken to rule out infection. This was negative. The inflamed areas did respond to steroid treatment but returned quickly once this was discontinued. She was beginning to feel frustrated, uncomfortable, her mood became low and she began to isolate herself from family and friends. Alternative pouching systems were trialed in case she had developed a sensitivity to the adhesive. None of these pouching systems made any difference to the irritation and she felt they leaked frequently. She went back to her reliable one-piece soft convex pouching system each time.

Interventions

A two-piece pouching system with a **CeraPlus** convex skin barrier was chosen as she had problems with flat pouching systems leaking in the past. The two-piece pouching system allowed her to change the skin barrier every three days and the pouch daily. Over the course of two weeks, the peristomal skin showed significant improvement And she reported relief from soreness and itching (**Photo 2**).

continued on back

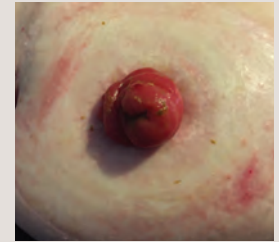

Photo 1 Areas of irritated peristomal skin.

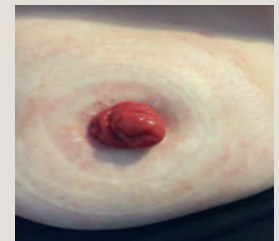


Photo 2 Improvement seen to peristomal skin after two weeks.

Use of a CeraPlus Skin Barrier with Remois Technology*

Contributing Author and Affiliations

Ann Goodey RGN Dip He BSc
Clinical Nurse Specialist in Stoma Care
Hollister Limited

Case Study 2

Outcomes

Before trying the two-piece pouching system with a CeraPlus convex skin barrier, this patient had become despondent and felt she would have to live with either regular steroid treatment, or irritation. The irritation has not returned and she feels much less anxious. This allowed her to gradually rebuild her confidence and resume her social activities.

Conclusion

Many people with ostomies experience peristomal skin issues and accept them as a normal aspect of having a stoma³. Thankfully, this patient sought help and the problem was resolved. Achieving a good fit around the stoma and preventing leakage as a means of mitigating skin irritation is important. The formulation of a skin barrier also has an impact on the health of the peristomal skin. Finding the right combination of skin barrier formulation, and skin barrier fit is essential to maintaining a healthy peristomal skin environment.

References:

1. Richbourg L, Thorpe J, Rapp C. *Difficulties experienced by the ostomate after hospital discharge.* J Wound Ostomy Continence Nurs. 2007; 34(1):70.
2. Meisner S, Lehur P-A, Moran B, Martins L, Jemec GBE. *Peristomal Skin Complications Are Common, Expensive, and Difficult to Manage: A Population Based Cost Modeling Study.* PLoS ONE. 2012; 7(5): e37813.
3. Whiteley IA and Sinclair G A *Review of Peristomal Skin Complications Following the Formation of an Ileostomy, Colectomy or Ileal Conduit.* World council of Enterostomal Therapists Journal, 2010; 30(3) p. 23-29.

The support of Hollister Incorporated is gratefully acknowledged.

This case study represents one nurse's experience in using a two-piece pouching system with a CeraPlus convex skin barrier with a specific patient and may not necessarily be replicated.



*Remois is a technology of Alcare Co., Ltd.

Prior to use, be sure to read the Instructions for Use for information regarding Intended Use, Contraindications, Warnings, Precautions, and Instructions.



Not all products are CE marked.

The Hollister logo and CeraPlus are trademarks of Hollister Incorporated. All other trademarks and copyrights are the property of their respective owners. © 2016 Hollister Incorporated



Hollister Incorporated
2000 Hollister Drive
Libertyville, Illinois 60048 USA
1.800.323.4060

www.hollister.com